



Banff Sport Medicine

Standardized X-ray Views: Recommendations

- 1. Knee OA Series** (no fracture suspected)
 - Standing AP (both knees)
 - Standing PA 30 degrees flexion (both knees)
 - Standing Lateral 30 degrees flexion (affected knee only)
 - Patella skyline view (affected knee only)

- 2. Acute Knee Series** (fracture/loose body suspected)
 - AP
 - Both obliques
 - Lateral (cross table for suspected # or recent injury)

- 3. Acute Shoulder Series** (fracture or dislocation suspected)
 - True AP (glenohumeral joint)
 - Trans-scapular
 - Axillary view (Lawrence preferred)

- 4. Chronic Shoulder Instability Series** (recurrent shoulder instability)
 - True AP in internal rotation (glenohumeral joint)
 - Stryker Notch View (to detect Hill-Sachs lesion)
 - West point Axillary View (to assess anterior glenoid rim)

- 5. Rotator Cuff Series** (chronic shoulder pain)
 - True AP (glenohumeral joint)
 - Zanca view (AC Joint, 10-15 degree cephalic)
 - Rockwood view (AP 45 degree caudal, centered to coracoid)

- 6. Patella Instability Series** (patella subluxation/dislocation)
 - AP
 - Lateral
 - Skyline view of the patella
 - Standing PA 30 degrees flexion (affected knee only)

7. Foot OA Series

- Weight-bearing AP
- Weight-bearing Lateral
- Non-weight-bearing oblique

8. Ankle OA Series

- Weight-bearing AP
- Weight-bearing Lateral
- Mortise
- 45 degree oblique

9. Hip Series

- Weight-bearing AP Pelvis including both hips
- Frog-leg lateral (if no fracture or dislocation suspected)
- Cross-table lateral (affected hip only, for OA or if FAI suspected)

10. Hand

- AP, Lateral, & Oblique

11. Wrist

- AP, Lateral, & Oblique

12. Elbow

- AP, Lateral, & internal and external oblique views

13. L-Spine

- AP, Lateral, L5/S1 spot if required

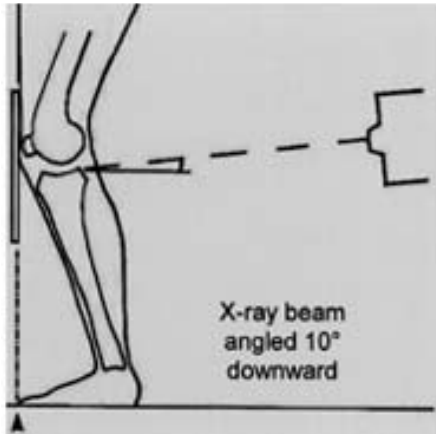
14. T-Spine

- AP, Lateral, Swimmers

15. C-Spine OA Series

- AP C3-C7 (Note: no odontoid view required)
- Lateral with swimmers if required
- Both oblique views

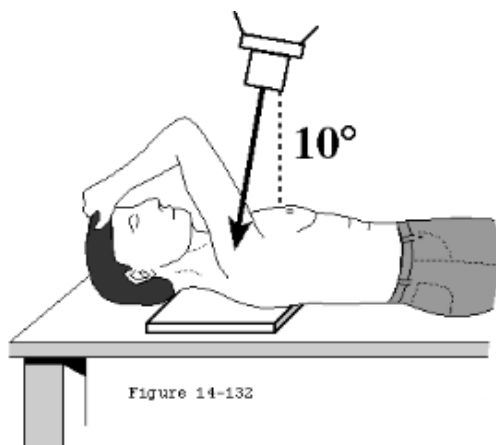
Additional Information: Views



Fixed flexion PA view (20° - 30° of knee flexion)

This figure illustrates the correct technique for performing the Fixed-flexion PA view. The patient's feet are placed in 10 degrees of internal rotation with the toes touching against the vertical table. The knees are then flexed until the anterior surface of the knees and thighs are leaning against the table. The x-ray beam is angulated 10 degrees caudal and centered on the knee. Joint space narrowing is best appreciated on this view, as

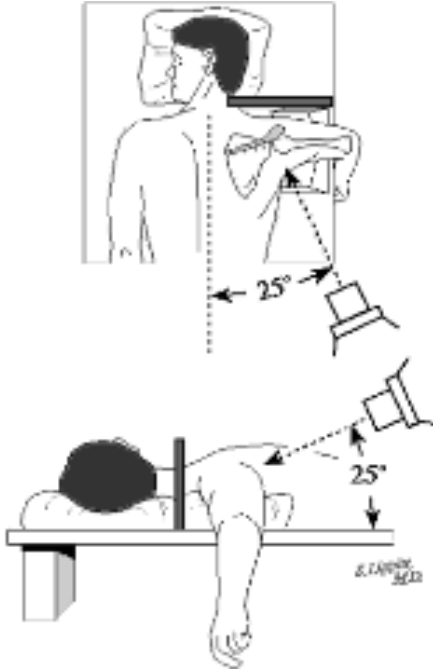
opposed to the Standing AP view, the purpose of which is to provide some information about the alignment of the knee.



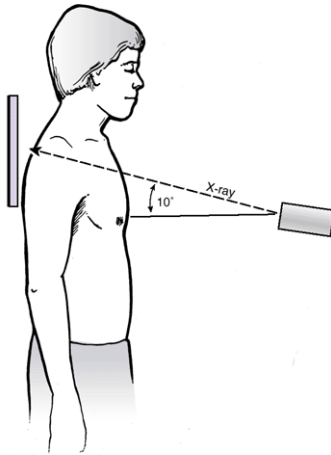
Stryker Notch view

This figure illustrates the Stryker Notch view. The palm of the hand of the affected shoulder is placed on top of the head, with the fingers directed toward the back of the head. The elbow of the affected shoulder should point straight upward. The x-ray beam tilts 10 degrees toward the head, centered over the coracoid process. This view is optimal for detecting a Hill-Sachs lesion (impaction fracture over the postero-superior humeral head that can occur after anterior dislocation(s)).

West Point Axillary view



This figure illustrates the West Point Axillary view. The patient is placed prone on the x-ray table with the involved shoulder on a pad raised 7.5 cm from the top of the table. The head is turned away from the involved side. With the cassette held against the superior aspect of the shoulder, the x-ray beam is centered at the axilla, 25 degrees downward from horizontal and 25 degrees medial. This view is used to demonstrate bony abnormalities of the anterior glenoid rim such as bony Bankart lesions or erosions of the anterior glenoid rim which can occur with recurrent anterior shoulder dislocations.



Zanca View

The above figure illustrates the Zanca view. The patient is upright with the beam directed at the AC joint with 10-15 degree cephalic tilt, using only 50% of the usual voltage penetration. This view is optimal for assessing degenerative change in the AC joint.

Rockwood View

The 30 caudal tilt view of Rockwood is an AP of the shoulder with the beam directed at the AC joint with a 30 degree caudal tilt. This view demonstrates the anterior-inferior projection of an acromial spur, if present. The spur will be seen projecting beyond the anterior edge of the distal clavicle. It is felt to be more clinically useful than the supraspinatus outlet view.